



**PATIENT**

Baldur Klein

**SPECIES**

Canine

**BREED**

Swedish Valhund

**SEX**

Male Intact

**AGE**

1.8 years

**WEIGHT**

33.5lbs

**PRESENTING CLINICAL SIGNS**

History: Baldur is referred to evaluate a heart murmur noted in April. He is clinically doing well with a good appetite and activity level. On exam: NSR , grade II/VI murmur with PMI left apical area, PSS, lung fields clear. BP: 170mmHg x 5 \*Sedated with propofol for study.

**ECHOCARDIOGRAM FINDINGS**

2D, m-mode, color flow and Doppler imaging is available.

**Left ventricle:** The LV diameter is normal with adequate myocardial function. LV wall thicknesses are normal.

**Left atrium:** The left atrium is normal.

**Mitral valve:** The mitral valve is mildly thickened with no prolapse into the left atrial lumen. Trivial mitral regurgitation.

**Aortic valve/Aorta:** The aortic valve is normal in morphology and mobility. Normal aortic outflow velocity; laminar flow. No aortic insufficiency.

**Right ventricle:** Normal right ventricular diameter and morphology indicating no overt evidence of pulmonary arterial hypertension.

**Right atrium:** Normal RA dimension.

**Tricuspid valve:** The tricuspid valve appears normal with no tricuspid regurgitation.

**Pulmonic valve/Pulmonary artery:** The pulmonic valve is normal in morphology and mobility. No pulmonic insufficiency. Normal RVOT velocity; laminar flow.

**Pericardium/other:** No pericardial or pleural effusion noted. No obvious cardiac masses.

**Heart rhythm:** ECG reveals a sinus rhythm with an average HR of 110bpm.

**2-Dimensional Measurements**

Ao diam (cm)	1.7
LA diam (cm)	2.3
LA:Ao (Swe)	1.3
IVS thickness (cm)	0.75
LVID diastole (cm)	3.3
PW thickness (cm)	0.73
LVID systole (cm)	2.3
FS (%)	30

**Doppler Measurements**

PV Vmax (m/s)	0.94
AoV Vmax (m/s)	1.5
MR Vmax (m/s)	NA
TR Vmax (m/s)	NA
TR PG (mmHg)	NA

**INTERPRETED BY**

Maggie Machen  
Lamy, DVM  
DACVIM (Cardiology)

**IMAGING**

**PERFORMED BY**

Pamela Harrigan,  
RDCS

**HOSPITAL NAME**

Mass Veterinary  
Services

**REFERRING VET**

Dr. Masloski

**INTERPRETATION OF THE FINDINGS**

Overtly normal cardiac structure and function. No cause of the murmur is identified in this study. Trivial MR is noted; however, this is unlikely to be heard on physical exam. In the absence of significant volume changes (dehydration) or anemia, other possibilities include a physiologic flow murmur only present with elevated heart rates (potentially masked by sedation), or a small flow abnormality not seen here. Baseline lab work is recommended if not recently performed. It is reasonable to monitor periodically via recheck echocardiography in the future, particularly should the murmur persist/progress. No significant valvular insufficiencies were noted, and no structural issues identified.

**RECOMMENDATIONS**

- No cardiac medications are indicated at this time. Monitor for any development of cough, labored breathing or exercise intolerance.
- No cardiac contraindication for general anesthesia.

**INVOICE**

25557

**DATE**

7/26/22



Mass Veterinary  
Services



**SonoPath**  
Clinical Sonography & Telectology  
EDUCATIONAL TELECONSULTATION SERVICES™  
1-800-838-4268 info@sonopath.com SonoPath.com

**PATIENT**

Baldur Klein

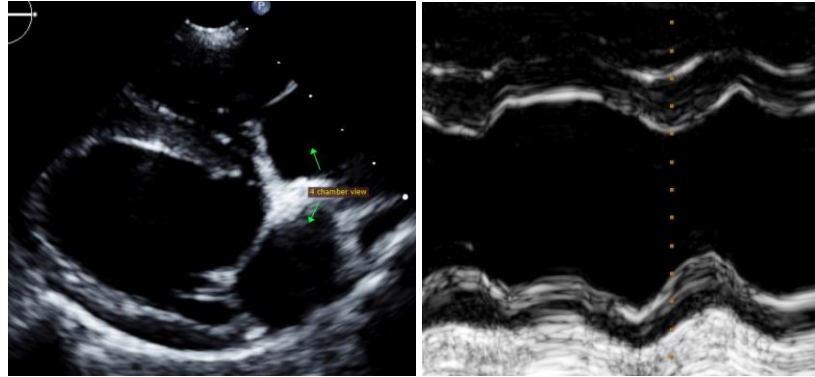
**PLAN**

- Recommend recheck echocardiogram in 12-18 months to screen for progression or development of concurrent cardiac disease that the preexisting murmur may mask.

**SPECIES**

Canine

**IMAGES**



**BREED**

Swedish Valhund

**SEX**

Male Intact

**AGE**

1.8 years

The information and recommendations provided are based on the images presented by the referring veterinarian. No evaluation can be communicated regarding pathology that was not visible in the image/video clips provided.

**WEIGHT**

33.5lbs

Thank you for this referral. This report was generated using transcription software, and minor dictation errors may be present. If the clinical or image interpretation does not parallel your findings or if I can be of any further assistance, please contact me.

**INTERPRETED BY**

Maggie Machen  
Lamy, DVM  
DACVIM (Cardiology)

Maggie Machen Lamy, DVM  
Diplomate of the American College of Veterinary Internal Medicine (Cardiology)  
info@sonopath.com

**Echocardiogram performed by:**

Pamela Harrigan, RDCS  
Pet Animal Ultrasound Service (4paus.com)

**IMAGING PERFORMED BY**

Pamela Harrigan,  
RDCS

**HOSPITAL NAME**

Mass Veterinary  
Services

**REFERRING VET**

Dr. Masloski

**INVOICE**

25557

**DATE**

7/26/22